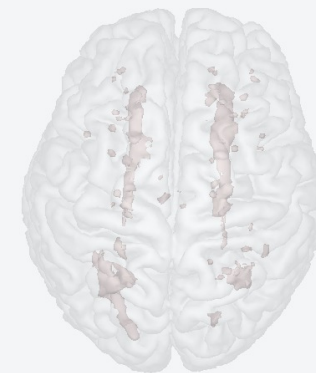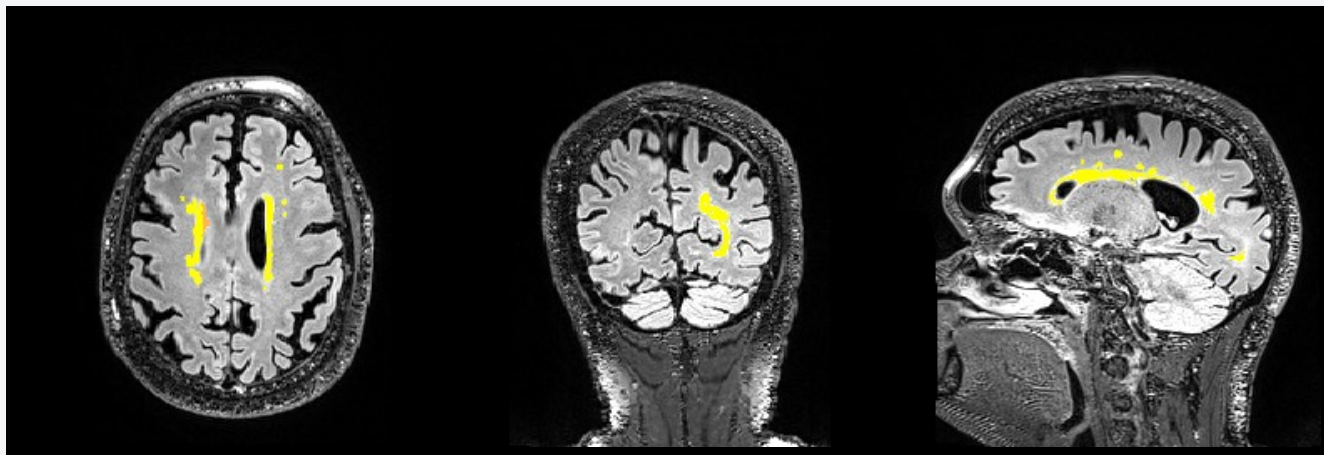


Name	Personal ID	Date of Birth	Sex	Study date
Tristan Brain Injury	DEMO	1947-07-01	Male	2019-04-30

FLAIR: Approved

QC



Lesions

Corpus callosum
 Lobar white matter
 Cerebellum
 Brainstem

LEFT RIGHT

Volumes	Corpus callosum	Lobar white matter	Cerebellum	Brainstem
Volume	0.3	8.8	0.0	0.1