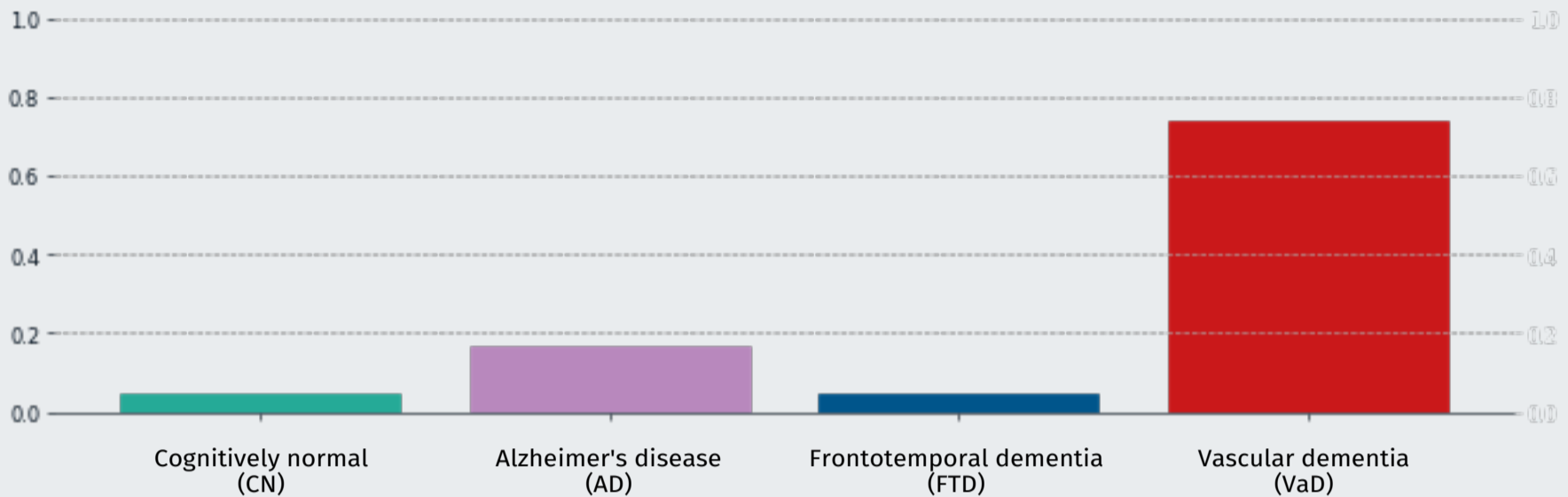


Name	Personal ID	Date of Birth	Sex	Study date
Victor Vascular	VaD_Case	1943-07-01	Male	2010-06-18

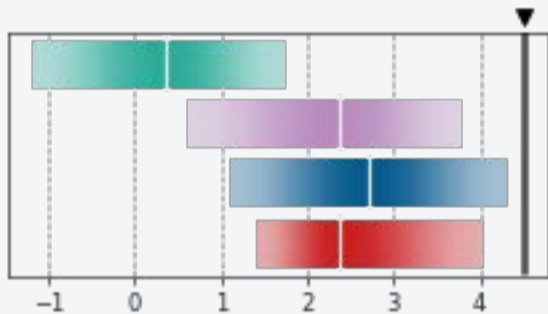
Probabilities for different etiologies



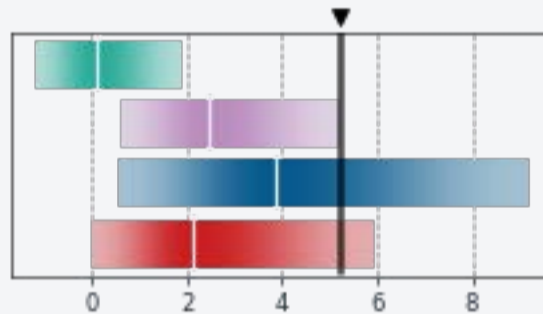
Summary

Cortical atrophy score	Hippocampal atrophy score left	Hippocampal atrophy score right	Anterior vs. posterior score	Volume of white-matter hyperintensities
4.50 (≥99th)	5.21 (≥99th)	7.52 (≥99th)	-1.35 (8th)	70.28 (≥99th)

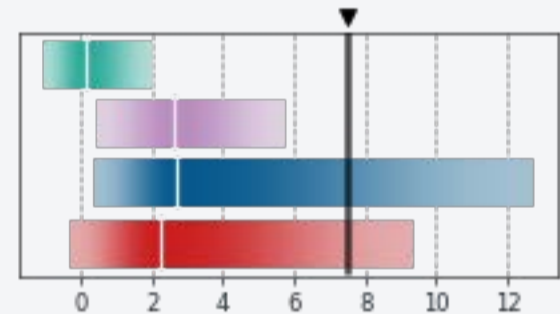
Cortical atrophy score



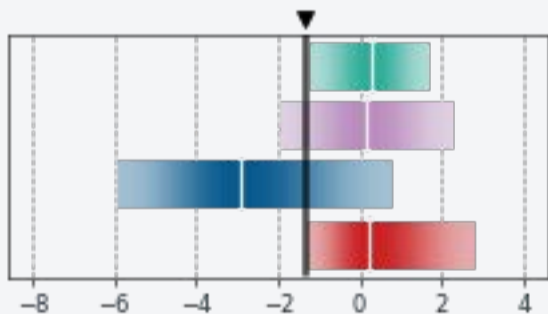
Hippocampal atrophy score left



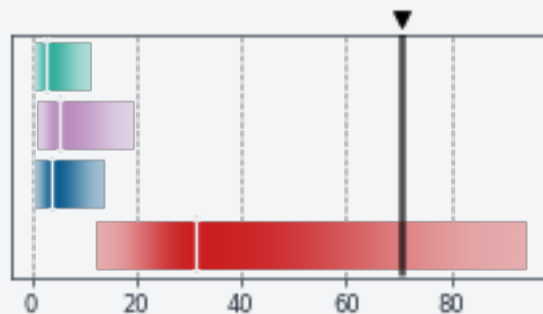
Hippocampal atrophy score right



Anterior vs. posterior score



Volume of white-matter hyperintensities



Comparison to diagnostic groups

- Cognitively normal (CN)
- Alzheimer's disease (AD)
- Frontotemporal dementia (FTD)
- Vascular dementia (VaD)

▼ Patient's value

