Combinostics

cMRI: TBI Report General morphometry

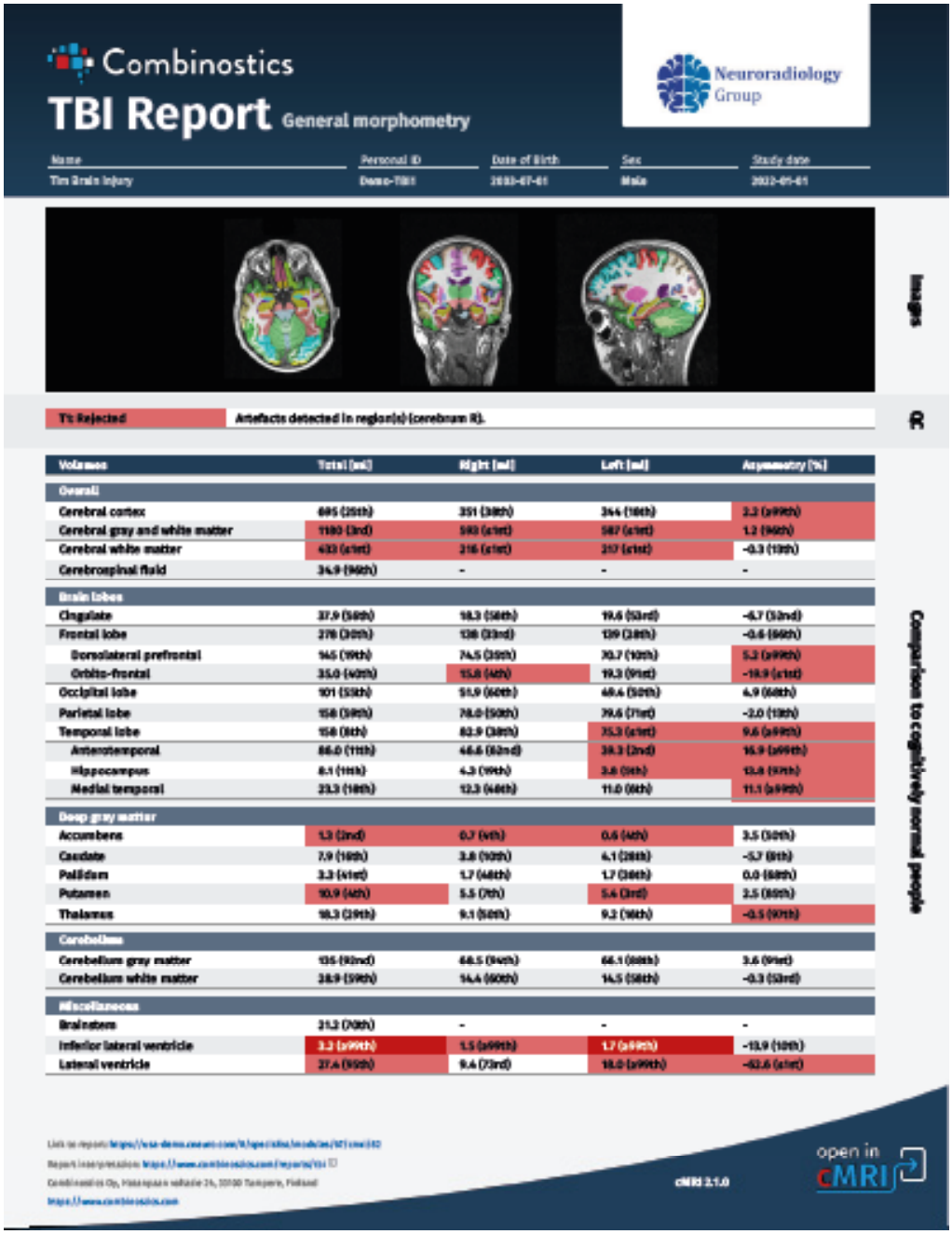

Combinostics

TBI Report General morphometry

Neuroradiology Group

Name	Personal ID	Date of Birth	Sex	Study date
Tim Brain Injury	Demo-TBI1	2003-07-01	Male	2022-01-01

Images

T1: Rejected	Artefacts detected in region(s) (cerebrum R).

QC

Comparison to cognitively normal people

Volumes	Total [ml]	Right [ml]	Left [ml]	Asymmetry [%]
Overall				
Cerebral cortex	695 (25th)	351 (38th)	344 (16th)	2.2 (≥99th)
Cerebral gray and white matter	1180 (3rd)	593 (≤1st)	587 (≤1st)	1.2 (96th)
Cerebral white matter	433 (≤1st)	216 (≤1st)	217 (≤1st)	-0.3 (13th)
Cerebrospinal fluid	34.9 (96th)	-	-	-
Brain lobes				
Cingulate	37.9 (58th)	18.3 (58th)	19.6 (53rd)	-6.7 (32nd)
Frontal lobe	278 (30th)	138 (33rd)	139 (28th)	-0.6 (66th)
Dorsolateral prefrontal	145 (19th)	74.5 (39th)	70.7 (10th)	5.2 (≥99th)
Orbito-frontal	35.0 (40th)	15.8 (4th)	19.3 (91st)	-19.9 (≤1st)
Occipital lobe	101 (53th)	51.9 (60th)	49.4 (50th)	4.9 (68th)
Parietal lobe	158 (39th)	78.0 (50th)	79.6 (71st)	-2.0 (13th)
Temporal lobe	158 (8th)	82.9 (38th)	75.3 (≤1st)	9.6 (≥99th)
Anterotemporal	86.0 (11th)	46.6 (62nd)	38.3 (2nd)	16.9 (≥99th)
Hippocampus	8.1 (11th)	4.3 (19th)	3.8 (1th)	13.8 (97th)
Medial temporal	23.3 (18th)	12.3 (46th)	11.0 (6th)	11.1 (≥99th)
Deep gray matter				
Accumbens	1.3 (2nd)	0.7 (4th)	0.6 (4th)	3.5 (30th)
Caudate	7.9 (16th)	3.8 (10th)	4.1 (28th)	-5.7 (8th)
Pallidum	3.3 (≤1st)	1.7 (48th)	1.7 (38th)	0.0 (88th)
Putamen	10.9 (4th)	5.5 (7th)	5.6 (3rd)	2.5 (89th)
Thalamus	18.3 (39th)	9.1 (58th)	9.2 (16th)	-0.5 (97th)
Cerebellum				
Cerebellum gray matter	135 (92nd)	68.5 (94th)	66.1 (88th)	3.6 (91st)
Cerebellum white matter	28.9 (59th)	14.4 (60th)	14.5 (58th)	-0.3 (53rd)
Miscellaneous				
Brainstem	31.2 (70th)	-	-	-
Inferior lateral ventricle	3.2 (≥99th)	1.5 (≥99th)	1.7 (≥99th)	-13.9 (10th)
Lateral ventricle	27.4 (95th)	9.4 (73rd)	18.0 (≥99th)	-62.6 (≤1st)

Link to report: https://[illegible]

Report interpretation: https://www.combinostics.com/reports/tbi

Combinostics Oy, Hatanpaan valtatie 24, 33100 Tampere, Finland

https://www.combinostics.com

cMRI 2.1.0

open in cMRI

1 Patient information and study dates.

2 Visual overview: T1 Segmented images.

3 Bilateral and total volumes and asymmetry of volumes as well as their percentiles for multiple brain regions.

4 Link to report interpretation.

5 Add clinic logo or address.

6 Automatic quality control: T1 images.

7 Highlights (deep red or blue color) imaging biomarkers that deviate strongly (z-score <-4 or >+4) from healthy population.

8 Option to open exam in cMRI viewer.